

Diagnosis and Treatment of Early Stage Testicular Cancer: AUA Guideline



Andrew Stephenson, Scott E. Eggener, Eric B. Bass, David M. Chelnick, Siamak Daneshmand, Darren Feldman, Timothy Gilligan, Jose A. Karam, Bradley Leibovich, Stanley L. Liauw, Timothy A. Masterson, Joshua J. Meeks, Phillip M. Pierorazio, Ritu Sharma and Joel Sheinfeld

From the American Urological Association Education and Research, Inc., Linthicum, Maryland

Abbreviations and Acronyms

AFP = alpha-fetoprotein
AUA = American Urological Association
BEP = bleomycin, etoposide, cisplatin
CT = computerized tomography
EP = etoposide, cisplatin
GCNIS = germ cell neoplasia in situ
GCT = germ cell tumor
HCG = human chorionic gonadotropin
IGCCCG = International Germ Cell Cancer Collaborative Group
LDH = lactate dehydrogenase
PET = positron emission tomography
PFS = progression-free survival
RPLND = retroperitoneal lymph node dissection
RT = radiation therapy
STM = serum tumor markers
TSS = testis-sparing surgery
US = ultrasound

Purpose: Testis cancer is the most common solid malignancy in young males. The purpose of this guideline is to provide a useful reference on the effective evidence-based treatment of early stage testicular cancer.

Methods: The systematic review utilized to inform this guideline was conducted by a methodology team at the Johns Hopkins University Evidence-based Practice Center. The methodology team searched using PubMed®, Embase®, and the Cochrane Central Register of Controlled Trials (CENTRAL) from January 1980 through August 2018. The evidence review team also reviewed relevant systematic reviews and references provided by the panel to identify articles that may have been missed by the database searches.

Results: When sufficient evidence existed, the body of evidence was assigned a strength rating of A (high), B (moderate), or C (low). Such evidence-based statements are provided as Strong, Moderate, or Conditional Recommendations. In instances of insufficient evidence, additional guidance is provided as Clinical Principles and Expert Opinions.

Conclusions: This guideline attempts to improve a clinician's ability to evaluate and treat patients with testicular cancer, but higher quality evidence in future trials will be essential to improve level of care for these patients.

Key Words: testicular neoplasms; carcinoma, embryonal; seminoma; teratoma

PURPOSE

The majority of men with testis cancer have low-stage disease. A priority for those patients with low-stage disease is limiting the burden of therapy and treatment-related toxicity without compromising cancer control. Testis cancer is a relatively rare malignancy, and outcomes are defined by specific cancer- and patient-related factors. Paradigms for management have undergone substantial change in recent years as evidence regarding risk stratification, recurrence, survival, and treatment-related toxicity has emerged.

METHODOLOGY

The Johns Hopkins University Evidence-based Practice Center team searched PubMed®, Embase®, and the Cochrane Central Register of Controlled Trials (CENTRAL) from January 1980 through August 2018. The team developed a search strategy by using medical subject heading (MeSH) terms and key words relevant to the diagnosis and treatment of early stage testicular cancer. A full description of the AUA methodology system and an overview of the AUA Nomenclature System can be found in the supplementary unabridged guideline (<https://www.jurology.com>).

Accepted for publication April 20, 2019.
The complete unabridged version of the guideline is available at <https://www.jurology.com>.
This document is being printed as submitted independent of editorial or peer review by the editors of *The Journal of Urology*®.

GUIDELINE STATEMENTS

The statements provided herein should be used in conjunction with the associated algorithm (figs. 1–3).

Initial Management

Diagnosis and Initial Consultation.

1. A solid mass in the testis identified by physical exam or imaging should be managed as a malignant neoplasm until proven otherwise. (Clinical Principle)
2. In a man with a solid mass in the testis suspicious for malignant neoplasm, serum tumor markers (STM) (alpha-fetoprotein [AFP], human chorionic gonadotropin [hCG], lactate dehydrogenase [LDH]) should be drawn and measured prior to any treatment, including orchiectomy. (Moderate Recommendation; Evidence Level: Grade C)
3. Prior to definitive management, patients should be counseled about the risks of hypogonadism and infertility (Moderate Recommendation; Evidence Level: Grade C); and should be offered sperm banking, when appropriate. In patients without a

DIAGNOSIS AND TREATMENT OF EARLY STAGE TESTICULAR CANCER: AUA GUIDELINE ALGORITHM

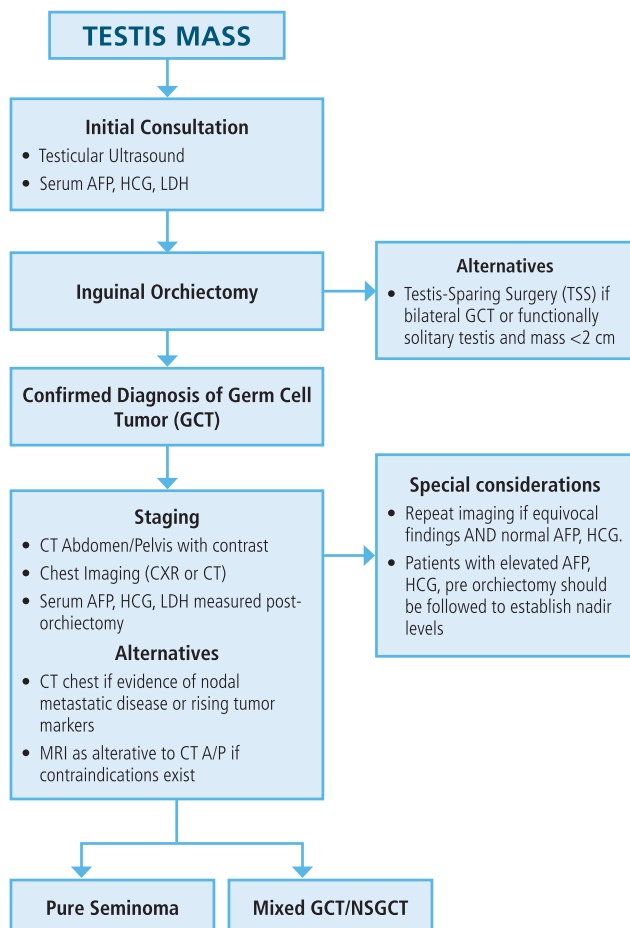
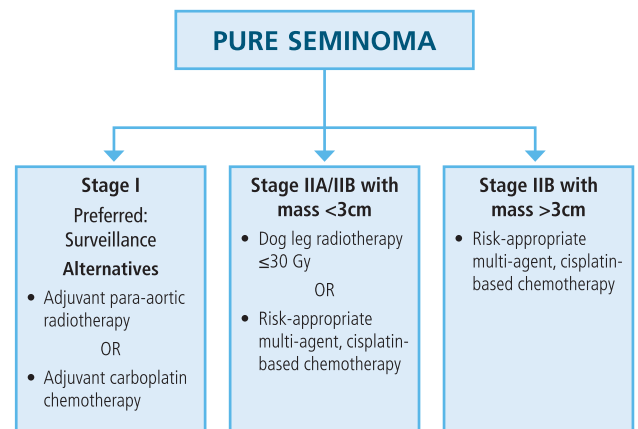


Figure 1. Testis mass

DIAGNOSIS AND TREATMENT OF EARLY STAGE TESTICULAR CANCER: AUA GUIDELINE ALGORITHM



*IGCCCG good risk chemotherapy BEP₃ or EP₄.

Figure 2. Pure seminoma

normal contralateral testis or with known subfertility, this should be considered prior to orchiectomy. (Clinical Principle)

4. Scrotal ultrasound (US) with Doppler should be obtained in patients with a unilateral or bilateral scrotal mass suspicious for neoplasm. (Strong Recommendation; Evidence Level: Grade B)

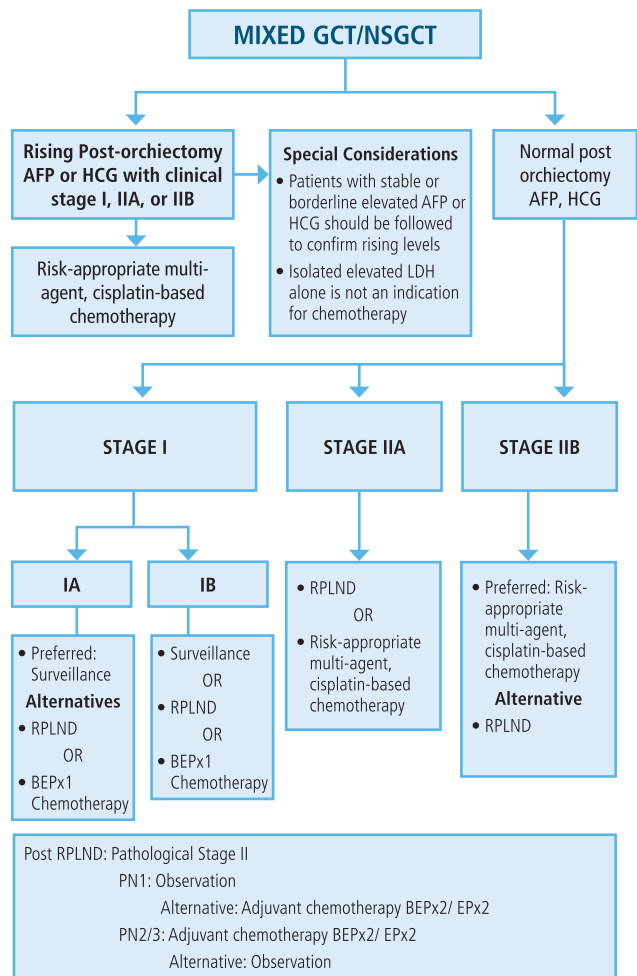
5. Testicular microlithiasis in the absence of solid mass and risk factors for developing germ cell tumor (GCT) does not confer an increased risk of malignant neoplasm and does not require further evaluation. (Moderate Recommendation; Evidence Level: Grade C)

6. Patients with normal STM (hCG and AFP) and indeterminate findings on physical exam or testicular US for testicular neoplasm should undergo repeat imaging in 6-8 weeks. (Clinical Principle)

7. MRI should not be used as the initial evaluation and diagnosis of a testicular lesion suspicious for neoplasm. (Moderate Recommendation; Evidence Level: Grade C)

Suspicion for testicular cancer should prompt scrotal US and STM. Any hypoechoic mass with vascular flow is highly suggestive of malignancy. Testicular microlithiasis is >5 small echogenic non-shadowing foci.¹ A prospective study showed no association with development of GCT.² Therefore, men with incidentally detected microlithiasis should not undergo further evaluation unless other risk factors are present (i.e. cryptorchidism, family history, personal history of GCT, or Germ Cell Neoplasia In Situ [GCNIS]).³ Up to 50-80% of non-palpable or incidentally detected masses < 2 cm are not cancerous.⁴ Management options include serial examinations and repeat US in 6-8 weeks, inguinal orchiectomy or testis-sparing surgery (TSS) with intraoperative frozen-section (table 1).

DIAGNOSIS AND TREATMENT OF EARLY STAGE TESTICULAR CANCER: AUA GUIDELINE ALGORITHM



*IGCCCG good risk chemotherapy BEP3 or EPx4. Intermediate or poor risk BEP4.

Figure 3. Mixed GCT/NSGCT

Standard management of a testicular mass concerning for cancer is radical inguinal orchiectomy. Pre-orchietomy STM levels are essential to interpret post-orchietomy changes, establish staging and determine appropriate therapy. At diagnosis, up to 50% of men have impaired semen parameters and 10% are azoospermic.⁵ Men who are undecided or planning future paternity should be offered sperm cryopreservation. In patients with an absent or abnormal contralateral testis or with known subfertility, sperm banking may be offered prior to orchiectomy.

Based on a systematic review, MRI does not have a clear diagnostic benefit compared to US but can be considered when US lesions are suspicious for benign etiology.

Orchiectomy.

8. Patients with a testicular lesion suspicious for malignant neoplasm and a normal contralateral testis

Table 1. Definition of the germ cell consensus classification¹²

Good Prognosis	
Nonseminoma	Seminoma
Testis/retroperitoneal primary and No non-pulmonary visceral metastases and Good markers- all of AFP < 1000 ng/ml and hCG < 5000 IU/l (1000 ng/ml) and LDH < 1.5 x upper limit of normal 56% of nonseminomas 5 year PFS 89% 5 year Survival 92%	Any primary site and No non-pulmonary visceral metastases and Normal AFP, any hCG, any LDH 90% of seminomas 5 year PFS 82% 5 year Survival 86%
Intermediate Prognosis	
Nonseminoma	Seminoma
Testis/retroperitoneal primary and No non-pulmonary visceral metastases and Intermediate markers- any of: AFP ≥ 1000 and ≤ 10,000 ng/ml or hCG ≥ 5000 IU/l and ≤ 50,000 IU/l or LDH ≥ 1.5 x N and ≤ 10 x N 28% of nonseminomas 5 year PFS 75% 5 year Survival 80%	Any primary site and Non-pulmonary visceral metastases and Normal AFP, any hCG, any LDH 10% of seminomas 5 year PFS 67% 5 year Survival 72%
Poor Prognosis	
Nonseminoma	Seminoma
Mediastinal primary or Non-pulmonary visceral metastases or Poor markers- any of: AFP > 10,000 ng/ml or hCG > 50,000 IU/l (10000 ng/ml) or LDH > 10 x upper limit of normal 16% of nonseminomas 5 year PFS 41% 5 year Survival 48%	No patients classified as poor prognosis

should undergo a radical inguinal orchiectomy; TSS is not recommended. Transscrotal orchiectomy is discouraged. (Strong Recommendation; Evidence Level: Grade B)

9. Testicular prosthesis should be discussed prior to orchiectomy. (Expert Opinion)

10. Patients who have undergone scrotal orchiectomy for malignant neoplasm should be counseled regarding the increased risk of local recurrence and may rarely be considered for adjunctive therapy (excision of scrotal scar or radiotherapy) for local control. (Moderate Recommendation; Evidence Level: Grade C)

Testis-Sparing Surgery.

11a. TSS through an inguinal incision may be offered as an alternative to radical inguinal orchiectomy in highly selected patients wishing to preserve gonadal function with masses < 2cm and (1) equivocal US/physical exam findings and negative tumor markers (hCG and AFP), (2) congenital, acquired or functionally solitary testis, or

(3) bilateral synchronous tumors. (Conditional Recommendation; Evidence Level: Grade C).

11b. Patients considering TSS should be counseled regarding: (1) higher risk of local recurrence, (2) need for monitoring with physical examination and US, (3) role of adjuvant radiotherapy to the testicle to reduce local recurrence, (4) impact of radiotherapy on sperm and testosterone production and (5) the risk of testicular atrophy and need for testosterone replacement therapy, and/or subfertility/infertility. (Moderate Recommendation; Evidence Level C).

11c. When TSS is performed, in addition to the suspicious mass, multiple biopsies of the ipsilateral testicle normal parenchyma should be obtained for evaluation by an experienced genitourinary pathologist. (Moderate Recommendation; Evidence Level: Grade C).

Clinical findings suggestive of GCT and a normal contralateral testis, radical orchiectomy is the treatment of choice. Patients may choose to have a testicular prosthesis at orchiectomy or a delayed implantation. Trans-scrotal approach to biopsy or orchiectomy are not recommended if malignancy is suspected since local recurrence rates are higher. TSS (or partial orchiectomy) can be considered when patients who desire to preserve hormone and fertility function have a high-likelihood of harboring a benign testicular tumor, an anatomically or functionally solitary testicle, or bilateral synchronous malignancies. Intraoperative frozen section of the mass with an experienced pathologist is recommended.⁶ Biopsies of adjacent normal parenchyma are recommended to evaluate for GCNIS and present in up to 90% of testicular GCT's.⁷ Complications after TSS include testicular atrophy requiring androgen replacement therapy.

GCNIS Counseling and Management.

12. Clinicians should inform patients with a history of GCT or GCNIS of risks of a second primary tumor while rare is significantly increased in the contralateral testis. (Moderate Recommendation; Evidence Level: Grade B).

13a. In patients with GCNIS on testis biopsy or malignant neoplasm after TSS, clinicians should inform patients of the risks/benefits of surveillance, radiation, and orchiectomy. (Moderate Recommendation; Evidence Level: Grade C).

13b. Clinicians should recommend surveillance in patients with GCNIS or malignant neoplasm after TSS who prioritize preservation of fertility and testicular androgen production. (Moderate Recommendation; Evidence Level: Grade C).

13c. Clinicians should recommend testicular radiation (18-20 Gy) or orchiectomy in patients with GCNIS or malignant neoplasm after TSS who prioritize reduction of cancer risk taking into consideration that radiation reduces the risk of hypogonadism compared to

orchiectomy. (Moderate Recommendation; Evidence Level: Grade C).

Among patients with GCT, there is a lifetime 2% risk of a contralateral GCT, increased in the setting of testicular atrophy, cryptorchidism, or younger age at presentation.⁸ Routine testicular self-examination is recommended. If GCNIS is present on biopsy, the risk of GCT is 50% over the subsequent 5 years.⁹ Management options for GCNIS include surveillance, radiation, or orchiectomy. Chemotherapy is not recommended.

Surveillance is encouraged in those who future paternity without requiring assisted reproductive techniques. Close monitoring and compliance with follow-up are essential. Among 122 men with GCNIS treated with 18-20 Gy and a contralateral testicular cancer, 3 (2.5%) had GCNIS on follow-up biopsy and 70% did not require treatment for hypogonadism.¹⁰ Lower doses of radiation (14-16 Gy) have been investigated with similarly low rates of GCNIS on follow-up biopsy (0-7%) and potentially lower rates of hypogonadism.¹¹ Radiation therapy (RT) at either dose eliminates spermatogenesis. Orchiectomy eliminates the risk of testicular cancer, lowers rates of fertility and testosterone levels, and is unnecessary for those not destined to develop cancer. Cisplatin-based chemotherapy is discouraged since 18-100% have GCNIS on subsequent biopsy.

Staging

Serum Tumor Markers.

14. Nadir STM (AFP, hCG and LDH) should be repeated at appropriate T1/2 time intervals after orchiectomy for staging and risk stratification. (Moderate Recommendation; Evidence Level: Grade B)

15. For patients with elevated AFP or hCG post-orchiectomy, clinicians should monitor STM to establish nadir levels before treatment only if marker nadir levels would influence treatment. (Clinical Principle)

16. For patients with metastatic GCT (Stage IIC or III) requiring chemotherapy, clinicians must base chemotherapy regimen and number of cycles on the International Germ Cell Cancer Collaborative Group (IGCCCG) risk stratification. IGCCCG risk stratification is based on NADIR STM (hCG, AFP and LDH) levels obtained prior to the initiation of chemotherapy, staging imaging studies, and tumor histology following radical orchiectomy (Strong Recommendation; Evidence Level: Grade A). Any post-pubertal male, regardless of age, should be treated according to adult treatment guidelines. (Moderate Recommendation; Evidence Level: Grade B).

17. For patients in whom STM (AFP and hCG) levels are borderline elevated (within 3x upper limit of normal) post-orchiectomy, a rising trend should be confirmed before management decisions are made as false positive elevations may occur. (Clinical Principle)

Imaging.

18. In patients with newly diagnosed GCT, clinicians must obtain a computed tomography (CT) scan of the abdomen and pelvis with IV contrast or MRI if contraindications to CT. (Strong Recommendation; Evidence Level: Grade B)

19a. In patients with newly diagnosed GCT, clinicians must obtain chest imaging. (Clinical Principle)

19b. In the presence of elevated and rising post-orchietomy markers (hCG and AFP) or evidence of metastases on abdominal/pelvic imaging, chest x-ray or physical exam, a CT chest should be obtained. (Strong Recommendation; Evidence Level: Grade C)

19c. In patients with clinical stage I seminoma, clinicians should preferentially obtain a chest x-ray over a CT scan. (Moderate Recommendation; Evidence Level: Grade B)

19d. In patients with a non-seminoma GCT (NSGCT), clinicians may preferentially obtain a CT scan of the chest over a chest x-ray and should prioritize CT chest for those patients recommended to receive adjuvant therapy. (Conditional Recommendation; Evidence Level: Grade C)

20. In patients with newly diagnosed GCT, clinicians should not obtain a positron emission tomography (PET) scan for staging. (Strong Recommendation; Evidence Level: Grade B)

21. Patients should be assigned a TNM-s category to guide management decisions. (Strong Recommendation; Evidence Level: Grade B)

Adequate time must elapse to allow STM to normalize (half-life HCG: 24-36 hours; AFP: 5-7 days). Histology, presence/absence of non-pulmonary visceral metastasis, and post-orchietomy STM's establish IGCCCG risk group: good, intermediate, or poor-risk (table 2 in supplementary unabridged guideline, <https://www.jurology.com>).¹² Good-risk is treated with either bleomycin, etoposide, cisplatin (BEP) x3 or etoposide, cisplatin (EP) x4. Intermediate or poor-risk disease are treated with BEPx4. Inferior outcomes occur when post-pubertal males <18 years are treated according to pediatric rather than adult guidelines.¹³ Mild elevation of AFP or HCG, particularly without metastatic disease on imaging, should prompt consideration of an alternative etiology. Since retroperitoneal lymph nodes are the most frequent site of metastases, imaging is paramount. There is inadequate evidence to support MRI over CT. For thorax imaging, CT has increased sensitivity compared to chest X-ray (median 100%

vs. 76% in combined seminoma/nonseminoma) but chest X-ray has superior specificity (median 98% vs. 93%).^{14,15} Skip metastases to the thorax are more common in nonseminoma than seminoma, where it approaches 0%. For men with clinical stage I non-seminoma who are undergoing Retroperitoneal Lymph Node Dissection (RPLND) or chemotherapy, CT chest is recommended (table 2).

PET scan has excellent specificity and positive predictive value (100% each) for seminoma but does not lead to substantive alterations in management.^{16,17} In nonseminoma, PET has favorable operating characteristics but the only prospective study did not show significant overall benefit compared to CT.¹⁸ Given the cost, radiation exposure, and cascade testing from false positive findings, the harms appear to outweigh the benefits of PET for initial staging.

Management**Principles of Management.**

22. Management decisions should be based on imaging obtained within the preceding 4 weeks and STM (hCG and AFP) within the preceding 10 days. (Expert Opinion)

23. Management decisions should be made in a multi-disciplinary setting involving experienced clinicians in urology, medical oncology, radiation oncology, pathology, and radiology. (Clinical Principle)

24. Expert review of pathologic specimens should be considered in clinical scenarios where treatment decisions will be impacted. (Moderate Recommendation; Evidence Level: Grade C)

25. In patients with normal STM (hCG and AFP) and equivocal imaging findings for metastasis, clinicians may consider repeat imaging in six-eight weeks to clarify the extent of disease prior to making a treatment recommendation. (Clinical Principle)

Due to the rapid doubling time of many GCT, particularly NSGCTs, there is a risk of disease progression between staging studies and intervention (table 3).¹⁹ Therefore, risk adapted management decisions (e.g. RPLND for clinical stage IIA disease) should be made based on recent imaging and STM levels to avoid under treatment. Application of a multi-disciplinary disease management team has been demonstrated to significantly decrease the rates of overtreatment, decrease relapse and improve survival.²⁰ The pathological evaluation of testicular cancers is challenging due to heterogeneity of tumor and multiple histology elements often present in NSGCT. Review by expert

Table 2. Clinical stage I seminoma active surveillance follow-up

	Years 1–2	Years 3–5	> Year 5
History and physical CT abdomen ± pelvis	Every 4–6 months	Every 6–12 months	If clinically indicated

pathologists leads to alterations of histologic subtype in 4-6% with up to 27% of pathology reports revised overall.^{21,22} These pathologic changes can affect management and prognosis. Many patients with newly diagnosed GCT have equivocal imaging findings, not clearly consistent with localized or metastatic disease (e.g. borderline enlargement of lymph nodes in the retroperitoneum). Repeating imaging 6-8 weeks after the initial CT can be helpful in establishing the probable etiology and may avoid overtreatment and unnecessary toxicity.^{23,24}

Seminoma Management—Surveillance/RPLND/Chemotherapy/Radiation.

26. Clinicians should recommend surveillance after orchiectomy for patients with stage I seminoma. Adjuvant radiotherapy and carboplatin-based chemotherapy are less preferred alternatives. (Strong Recommendation, Evidence Level: Grade B)

For stage I seminoma, patients are candidates for surveillance, adjuvant carboplatin, or adjuvant RT after orchiectomy. Surveillance is associated with the lowest risk for short and long-term treatment-related morbidity, since more than 80% of patients will not experience recurrence and are cured with orchiectomy alone. Adjuvant carboplatin and radiation reduce the risk of relapse but do not improve cancer-specific survival compared to surveillance.²⁵

27. For patients with stage IIA or IIB seminoma with a lymph node ≤ 3 cm, clinicians should recommend RT or multi-agent cisplatin-based chemotherapy based on shared decision-making. (Moderate Recommendation; Evidence Level: Grade B) For patients with IIB seminoma with a lymph node > 3 cm, chemotherapy is recommended. (Moderate Recommendation; Evidence Level: Grade B).

RT and multi-agent chemotherapy both result in high rates of cancer specific survival ($>97\%$) in stage II seminoma. For patients with stage IIA seminoma, recurrence rates after radiation²⁶ or chemotherapy²⁷ are similar ($<10\%$). Studies of stage IIB seminoma suggest fewer relapses after chemotherapy compared to RT.²⁸

Nonseminoma Management-Surveillance/RPLND/Chemotherapy/Radiation.

28. Clinicians should recommend risk-appropriate, multi-agent chemotherapy for patients with NSGCT with elevated and rising post-orchiectomy serum AFP or beta-hCG (i.e. stage TanyN1-2S1). (Strong Recommendation; Evidence Level: Grade B)

Studies of men with stage I, IIA and IIB NSGCT with persistently elevated serum AFP or BHCG after orchiectomy have reported high relapse rates after primary RPLND.²⁹⁻³¹ Elevated STM after orchiectomy in these patients indicates a high probability of systemic disease for which primary chemotherapy is recommended.

29. Clinicians should recommend surveillance for patients with stage IA NSGCT. RPLND or one cycle of BEP chemotherapy are effective and appropriate alternative treatment options for patients who decline surveillance or are at risk for non-compliance. (Moderate Recommendation; Evidence Level: Grade B)

30. For patients with a stage IB NSGCT, clinicians should recommend surveillance, RPLND, or one or two cycles of BEP chemotherapy based on shared decision-making. (Strong Recommendation; Evidence Level: Grade B)

31. Patients with stage I NSGCT and any secondary somatic malignancy (also known as teratoma with malignant transformation) in the primary tumor at orchiectomy should undergo RPLND. (Expert Opinion)

Relapse rates for patients with clinical stage IA NSGCT is 10%-20% in most studies. Thus, 80%-90% of men are cured with orchiectomy alone.^{23,32} For these patients, surveillance is recommended. Some men may prefer active treatment with RPLND or one cycle of BEP chemotherapy in order to reduce the risk of relapse and the need for more extensive treatment should a relapse occur on surveillance.³³ Men with clinical stage IB NSGCT of the testis have a higher risk of relapse following orchiectomy (43-54%) compared to men with stage IA.^{32,34,35} As such, surveillance, RPLND, or one cycle of BEP chemotherapy are all acceptable options. Clinical stage I NSGCT patients with any secondary somatic malignancy in the primary tumor should undergo RPLND due to the insensitivity of these tumors to chemotherapy.^{36,37}

32. Clinicians should recommend RPLND or chemotherapy for patients with stage IIA NSGCT with normal post-orchiectomy serum (S0) AFP and beta-hCG. (Moderate Recommendation; Evidence Level: Grade B)

33. In patients with clinical stage IIB NSGCT and normal post-orchiectomy serum AFP and hCG, clinicians should recommend risk-appropriate, multi-agent chemotherapy. (Moderate Recommendation; Evidence Level: Grade B) Clinicians may offer RPLND as an alternative to chemotherapy to select patients with clinical stage IIB NSGCT with normal post-orchiectomy serum AFP and beta-hCG. (Conditional Recommendation; Evidence Level: Grade C)

Table 3. Clinical stage I NSGCT active surveillance follow-up

	Year 1	Year 2	Year 3	Year 4	Year 5	> Year 5
History, physical and tumor markers	Every 2–3 months	Every 2–4 months	Every 4–6 months	Every 6–12 months	Every 6–12 months	If clinically indicated
Chest x-ray and CT abdomen \pm pelvis	Every 3–6 months	Every 4–12 months	Once		Once	If clinically indicated

Men with stage IIA NSGCT have an excellent prognosis when treated with either RPLND or chemotherapy.^{12,38–40} Shared decision-making should be used to tailor the treatment decision to the patient's goals, values and medical history.⁴¹ Patients with clinical stage IIB NSGCT typically have pathological stage II disease confirmed if they undergo RPLND and may be advised to undergo two cycles of post-RPLND chemotherapy if non-teratoma GCT is found in the surgical specimen due to their high-risk of relapse.^{29,42,43} Therefore, chemotherapy is generally preferred over RPLND as initial post-orchietomy treatment for these patients.

34. Among patients who are candidates for RPLND, it is recommended clinicians consider referral to an experienced surgeon at a high-volume center. (Moderate Recommendation; Evidence Level: Grade C)

35. Surgeons with experience in the management of GCT and expertise in minimally invasive surgery may offer a minimally-invasive RPLND, acknowledging the lack of long-term data on oncologic outcomes. (Expert Opinion)

36. Primary RPLND should be performed with curative intent in all patients. RPLND should be performed with adherence to the following anatomical principles, regardless of the intent to administer adjuvant chemotherapy. These principles are applied to both open and minimally-invasive approaches. (Moderate Recommendation, Evidence Level: Grade B).

- A full bilateral template dissection should be performed in patients with suspicious lymph nodes based on CT imaging or intraoperative assessment and in those with somatic-type malignancy in the primary tumor.
- A full bilateral template or modified template dissection may be performed in patients with clinically negative lymph nodes.
- A right modified template dissection may omit the para-aortic lymph nodes below the inferior mesenteric artery. Omission of para-aortic lymph nodes above the inferior mesenteric artery is controversial.
- A left modified template dissection may omit paracaval, precaval, and retrocaval lymph nodes. Omission of interaortocaval lymph nodes is controversial.
- Nerve-sparing should be offered in select patients desiring preservation of ejaculatory function.
- Nerve-sparing attempts should not compromise the quality of the lymph node dissection.
- A complete retroaortic and/or retrocaval lymph node dissection with division of lumbar vessels should be performed when within the planned template.
- The ipsilateral gonadal vessels should be removed in all patients.
- The cephalad extent of the dissection is the crus of the diaphragm to the level of the renal arteries.

The caudad extent of disease is the crossing of the ureter over the ipsilateral common iliac artery.

RPLND is a technically complex surgery with removal of retroperitoneal lymph nodes while preserving the great vessels, surrounding organs, and ejaculatory nerves. Strong consideration for referral to an experienced testes cancer surgeon or center is advised. The role of minimally invasive RPLND in the management of GCT is controversial. RPLND should be performed with curative intent; RPLND should not be performed as a staging modality alone.

37. After primary RPLND, clinicians should recommend surveillance or adjuvant chemotherapy in patients with NSGCT who have pathological stage II disease that is not pure teratoma. For patients with pN1 and/or pN1-3 pure teratoma, surveillance is preferred. For patients with pN2-3 at RPLND, multi-agent cisplatin based chemotherapy is preferred. (Moderate Recommendation; Evidence Level: Grade B)

A randomized trial of adjuvant chemotherapy versus observation for pathological stage II disease after primary RPLND showed significant reduction in relapse but no difference in overall survival.⁴³ After RPLND alone, men with pN1 disease have a relapse rate of 10% whereas those with pN2 disease have recurrence rates of 58-93%.^{29,44,45} Two cycles of adjuvant chemotherapy reduces the relapse rate to 0-7%.^{43,44,46}

Surveillance for Stage I Testicular Cancer

38. For a patient with clinical stage I seminoma choosing surveillance, clinicians should obtain a history and physical examination and perform cross-sectional imaging of the abdomen with or without the pelvis, every 4-6 months for the first 2 years, and then every 6-12 months in years 3-5. Routine surveillance imaging of the chest and STM assessment can be obtained as clinically indicated. (Moderate Recommendation; Evidence Level: Grade B) (table 3 in supplementary unabridged guideline, <https://www.jurology.com>)

39. In patients with stage I NSGCT undergoing surveillance after orchietomy, a clinician should perform a physical examination and obtain STM (AFP, hCG +/- LDH) every 2-3 months in year 1, every 2-4 months in year 2, every 4-6 months in year 3, and every 6-12 months for years 4 and 5. (Moderate Recommendation; Evidence Level: Grade C)

For seminoma, the majority of relapses will be detected on abdominal-pelvic CT imaging.⁴⁷ The role of routine STM assessment and chest imaging in these patients is limited. Clinical stage I NSGCT patients on surveillance should be evaluated with routine STM and chest-abdominal-pelvic imaging.

40. In patients with stage I NSGCT undergoing surveillance after orchietomy, radiologic assessment (chest

x-ray and imaging of the abdomen plus or minus the pelvis) should be obtained every 3-6 months in year 1 starting at 3 months, every 4-12 months in year 2, once in year 3, and once in year 4 or 5. (Moderate Recommendation; Evidence Level: Grade B) Men at higher risk of relapse (e.g. lymphovascular invasion) should be imaged with shorter intervals. (Expert Opinion) (table 4 in supplementary unabridged guideline, <https://www.jurology.com>)

41. Patients who relapse on surveillance should be fully restaged and treated based on their TNM-s status. (Moderate Recommendation; Evidence Level: Grade C)

42. Clinicians should inform patients with stage I GCT on surveillance of the $\leq 1\%$ risk of late relapse after 5 years. (Moderate Recommendation; Evidence Level: B) Annual serologic and radiographic assessment may be performed thereafter as indicated based upon clinical concerns. (Clinical Principle).

Additional Survivorship

43. Patients with GCT should be monitored for signs and symptoms of hypogonadism. If present, serum AM testosterone and luteinizing hormone levels should be measured. (Clinical Principle)

44. Patients with a history of GCT whose treatment has included RT, chemotherapy, or both should be advised of elevated risk of cardiovascular disease (Conditional Recommendation; Evidence Level: Grade C) and should establish regular care with a primary care physician so modifiable risk factors for cardiovascular disease can be monitored (such factors include diet, exercise, smoking, serum lipid levels, blood pressure, and serum glucose). (Expert Opinion)

45. Patients with a history of GCT whose treatment has included RT, chemotherapy, or both should be advised of elevated risk of secondary malignancy (Conditional Recommendation; Evidence Level: Grade C) and should establish regular care with a primary care physician for appropriate health care maintenance and cancer screening as appropriate. (Expert Opinion)

Patients should be assessed for signs or symptoms of hypogonadism. RT and chemotherapy are associated with an increased risk of cardiovascular disease and secondary malignancies in testis cancer survivors.⁴⁸⁻⁵⁰ Regarding cardiovascular disease risk, it is appropriate to reduce known risk factors in a high-risk population. Additional cancer screening beyond what is recommended for the general population is not recommended for testis cancer survivors.

FUTURE DIRECTIONS

This guideline attempts to improve a clinician's ability to evaluate and treat patients with testicular cancer, but higher quality evidence in future trials will be essential to improve level of care for these patients.

DISCLAIMER

This document was written by the Testicular Cancer Guideline Panel of the American Urological Association Education and Research, Inc., which was created in 2017. The Practice Guidelines Committee (PGC) of the AUA selected the committee chair. Panel members were selected by the chair. Membership of the Panel included specialists in urology and primary care with specific expertise on this disorder. The mission of the panel was to develop recommendations that are analysis-based or consensus-based, depending on panel processes and available data, for optimal clinical practices in the treatment of early stage testicular cancer.

Funding of the panel was provided by the AUA. Panel members received no remuneration for their work. Each member of the panel provides an ongoing conflict of interest disclosure to the AUA.

While these guidelines do not necessarily establish the standard of care, AUA seeks to recommend and to encourage compliance by practitioners with current best practices related to the condition being treated. As medical knowledge expands and technology advances, the guidelines will change. Today these evidence-based guidelines statements represent not absolute mandates but provisional proposals for treatment under the specific conditions described in each document. For all these reasons, the guidelines do not pre-empt physician judgment in individual cases.

Treating physicians must take into account variations in resources, and patient tolerances, needs, and preferences. Conformance with any clinical guideline does not guarantee a successful outcome. The guideline text may include information or recommendations about certain drug uses ('off label') that are not approved by the Food and Drug Administration (FDA), or about medications or substances not subject to the FDA approval process. AUA urges strict compliance with all government regulations and protocols for prescription and use of these substances. The physician is encouraged to carefully follow all available prescribing information about indications, contraindications, precautions and warnings. These guidelines and best practice statements are not intended to provide legal advice about use and misuse of these substances.

Although guidelines are intended to encourage best practices and potentially encompass available technologies with sufficient data as of close of the literature review, they are necessarily time-limited. Guidelines cannot include evaluation of all data on emerging technologies or management, including those that are FDA-approved, which may immediately come to represent accepted clinical practices.

For this reason, the AUA does not regard technologies or management which are too new to be addressed by this guideline as necessarily experimental or investigational.

DISCLOSURES

All panel members completed COI disclosures. Disclosures listed include both topic- and non-topic-related relationships.

Consultant/Advisor: Siamak Daneshmand, MD: Photocure, Taris, Pacific Edge, Ferring; Scott E. Eggener, MD: Profound Medical, MDx Health, Janssen, Sopheris, Insightec; Jose A. Karam, MD: Novartis, Pfizer, EMD Serono; Joshua J. Meeks, MD, PhD: Ferring, AstraZeneca; Phillip M. Pierorazio, MD: National Comprehensive Cancer Network, Urogen Pharmaceuticals; Andrew Stephenson, MD: Genomic Health, Astellas

Meeting Participant or Lecturer: Siamak Daneshmand, MD: Photocure, Ferring; Scott E. Eggener, MD: MDx Health, Janssen, ASCO; Andrew Stephenson, MD: Genomic Health

Scientific Study or Trial: David Chelnick: Cleveland Clinic; Siamak Daneshmand, MD: Photocure; Scott E. Eggener, MD: Genomic Health, MDx Health,

Opko Health; Darren Feldman, MD: Seattle Genetics; Jose A. Karam, MD: Roche/Genentech, Mirati; Joshua J. Meeks, MD, PhD: Veteran's Health Administration, Merck, NextCure, NCI, AstraZeneca; Phillip M. Pierorazio, MD: Urogen Pharmaceuticals

Leadership Position: Timothy Gilligan, MD: National Cancer Institute; Phillip M. Pierorazio, MD: Testicular Cancer Awareness Foundation

Health Publishing: Scott E. Eggener, MD: World Journal of Urology, Journal of Urology, Canadian Journal of Urology, ASCO; Darren Feldman, MD: UpToDate, Seattle Genetics; Timothy Gilligan, MD: UpToDate; Jose A. Karam, MD: BJU International, Frontiers in Genitourinary Oncology, Annals of Surgical Oncology, Cancer

Other: David Chelnick: 4th Angel/Taussig Cancer Center (Cleveland Clinic), American Society of Anesthesiologists (ASA); Darren Feldman, MD: ASCO Genitourinary Oncology Guidelines Committee, NCCN Guidelines, NCCN; Bradley C. Leibovich, MD, FACS: AUA Guidelines Renal Mass panel, National Comprehensive Cancer Network-Prostate Cancer Guidelines Committee, Prostate Cancer Foundation, John Hanson Research Foundation, Epizyme, AbbVie, Tesaro, NCI

REFERENCES

- Winter TC, Kim B, Lowrance WT et al: Testicular microlithiasis: what should you recommend? *AJR Am J Roentgenol* 2016; **206**: 1164.
- DeCastro BJ, Peterson AC and Costabile RA: A 5-year followup study of asymptomatic men with testicular microlithiasis. *J Urol* 2008; **179**: 1420.
- Tan IB, Ang KK, Ching BC et al: Testicular microlithiasis predicts concurrent testicular germ cell tumors and intratubular germ cell neoplasia of unclassified type in adults: a meta-analysis and systematic review. *Cancer* 2010; **116**: 4520.
- Albers P, Albrecht W, Algaba F et al: Guidelines on testicular cancer: 2015 update. *Eur Urol* 2015; **68**: 1054.
- Hanson HA, Anderson RE, Aston KI et al: Sub-fertility increases risk of testicular cancer: evidence from population-based semen samples. *Fertil Steril* 2016; **105**: 322.
- Harari SE, Sassoon DJ, Priemer DS et al: Testicular cancer: the usage of central review for pathology diagnosis of orchiectomy specimens. *Urol Oncol* 2017; **35**: 605.
- Heidenreich A, Weissbach L, Hörtl W et al: Organ sparing surgery for malignant germ cell tumor of the testis. *J Urol* 2001; **166**: 2161.
- Harland SJ, Cook PA, Fossa SD et al: Intratubular germ cell neoplasia of the contralateral testis in testicular cancer: defining a high risk group. *J Urol* 1998; **160**: 1353.
- von der Maase H, Rorth M, Walbom-Jorgensen S et al: Carcinoma in situ of contralateral testis in patients with testicular germ cell cancer: study of 27 cases in 500 patients. *Br Med J (Clin Res Ed)* 1986; **293**: 1398.
- Dieckmann KP, Wilken S, Loy V et al: Treatment of testicular intraepithelial neoplasia (intratubular germ cell neoplasia unspecified) with local radiotherapy or with platinum-based chemotherapy: a survey of the German Testicular Cancer Study Group. *Ann Oncol* 2013; **24**: 1332.
- Petersen PM, Giwercman A, Daugaard G et al: Effect of graded testicular doses of radiotherapy in patients treated for carcinoma-in-situ in the testis. *J Clin Oncol* 2002; **20**: 1537.
- International germ cell consensus classification: a prognostic factor-based staging system for metastatic germ cell cancers. International Germ Cell Cancer Collaborative Group. *J Clin Oncol* 1997; **15**: 594.
- Shaikh F, Cullen JW, Olson TA et al: Reduced and compressed cisplatin-based chemotherapy in children and adolescents with intermediate-risk extracranial malignant germ cell tumors: a report from the children's oncology group. *J Clin Oncol* 2017; **35**: 1203.
- White PM, Adamson DJ, Howard GC et al: Imaging of the thorax in the management of germ cell testicular tumours. *Clin Radiol* 1999; **54**: 207.
- Fernandez EB, Colon E, McLeod DG et al: Efficacy of radiographic chest imaging in patients with testicular cancer. *Urology* 1994; **44**: 243.
- Ambrosini V, Zucchini G, Nicolini S et al: 18F-FDG PET/CT impact on testicular tumours clinical management. *Eur J Nucl Med Mol Imaging* 2014; **41**: 668.
- Hain SF, O'Doherty MJ, Timothy AR et al: Fluorodeoxyglucose PET in the initial staging of germ cell tumours. *Eur J Nucl Med* 2000; **27**: 590.
- de Wit M, Brenner W, Hartmann M et al: [18f]-fdg-pet in clinical stage i/ii non-seminomatous germ cell tumours: results of the German multicentre trial. *Ann Oncol* 2008; **19**: 1619.
- Stephenson AJ and Gilligan T: Neoplasms of the testis (in cambell-walsh urology, 11th edition), p. 784, 2015.
- Schrader AJ, Ohlmann CH, Rossmann S et al: Impact of evidence-based interdisciplinary guidelines on testis cancer management. *Cancer* 2006; **106**: 313.
- Delaney RJ, Sayers CD, Walker MA et al: The continued value of central histopathological review of testicular tumours. *Histopathology* 2005; **47**: 166.
- Lee AH, Mead GM and Theaker JM: The value of central histopathological review of testicular tumours before treatment. *BJU Int* 1999; **84**: 75.

23. Tandstad T, Dahl O, Cohn-Cedermark G et al: Risk-adapted treatment in clinical stage i non-seminomatous germ cell testicular cancer: the swenoteca management program. *J Clin Oncol* 2009; **27**: 2122.
24. Gilligan T, Lin DW, Aggarwal R et al: Testicular cancer: Nccn clinical practice guidelines in oncology. 2019: 73.
25. Kollmannsberger C, Tyldesley S, Moore C et al: Evolution in management of testicular seminoma: population-based outcomes with selective utilization of active therapies. *Ann Oncol* 2011; **22**: 808.
26. Classen J, Dieckmann K, Bamberg M et al: Radiotherapy with 16 gy may fail to eradicate testicular intraepithelial neoplasia: preliminary communication of a dose-reduction trial of the German testicular cancer study group. *Br J Cancer* 2003; **88**: 828.
27. Garcia-del-Muro X, Maroto P, Guma J et al: Chemotherapy as an alternative to radiotherapy in the treatment of stage iia and iib testicular seminoma: a Spanish germ cell cancer group study. *J Clin Oncol* 2008; **26**: 5416.
28. Tandstad T, Smaaland R, Solberg A et al: Management of seminomatous testicular cancer: a binational prospective population-based study from the Swedish Norwegian testicular cancer study group. *J Clin Oncol* 2011; **29**: 719.
29. Stephenson AJ, Bosl GJ, Motzer RJ et al: Retroperitoneal lymph node dissection for non-seminomatous germ cell testicular cancer: impact of patient selection factors on outcome. *J Clin Oncol* 2005; **23**: 2781.
30. Saxman SB, Nichols CR, Foster RS et al: The management of patients with clinical stage i non-seminomatous testicular tumors and persistently elevated serologic markers. *J Urol* 1996; **155**: 587.
31. Davis BE, Herr HW, Fair WR et al: The management of patients with nonseminomatous germ cell tumors of the testis with serologic disease only after orchiectomy. *J Urol* 1994; **152**: 111.
32. Kollmannsberger C, Moore C, Chi KN et al: Non-risk-adapted surveillance for patients with stage i nonseminomatous testicular germ-cell tumors: diminishing treatment-related morbidity while maintaining efficacy. *Ann Oncol* 2010; **21**: 1296.
33. Oldenburg J, Aparicio J, Beyer J et al: Personalizing, not patronizing: the case for patient autonomy by unbiased presentation of management options in stage I testicular cancer. *Ann Oncol* 2015; **26**: 833.
34. Daugaard G, Gundgaard MG, Mortensen MS et al: Surveillance for stage i nonseminoma testicular cancer: outcomes and long-term follow-up in a population-based cohort. *J Clin Oncol* 2014; **32**: 3817.
35. Sturgeon JF, Moore MJ, Kakiashvili DM et al: Non-risk-adapted surveillance in clinical stage i nonseminomatous germ cell tumors: the princess margaret hospital's experience. *Eur Urol* 2011; **59**: 556.
36. Donadio AC, Motzer RJ, Bajorin DF et al: Chemotherapy for teratoma with malignant transformation. *J Clin Oncol* 2003; **21**: 4285.
37. El Mesbahi O, Terrier-Lacombe MJ, Rebischung C et al: Chemotherapy in patients with teratoma with malignant transformation. *Eur Urol* 2007; **51**: 1306.
38. Ko JJ, Bernard B, Tran B et al: Conditional survival of patients with metastatic testicular germ cell tumors treated with first-line curative therapy. *J Clin Oncol* 2016; **34**: 714.
39. van Dijk MR, Steyerberg EW and Habbema JD: Survival of non-seminomatous germ cell cancer patients according to the IGCC classification: an update based on meta-analysis. *Eur J Cancer* 2006; **42**: 820.
40. Donohue JP, Thornhill JA, Foster RS et al: Clinical stage b non-seminomatous germ cell testis cancer: the Indiana university experience (1965–1989) using routine primary retroperitoneal lymph node dissection. *Eur J Cancer* 1995; **31**: 1599.
41. Elwyn G, Frosch D, Thomson R et al: Shared decision making: a model for clinical practice. *J Gen Intern Med* 2012; **27**: 1361.
42. Donohue JP, Thornhill JA, Foster RS et al: The role of retroperitoneal lymphadenectomy in clinical stage b testis cancer: the Indiana university experience (1965 to 1989). *J Urol* 1995; **153**: 85.
43. Williams SD, Stablein DM, Einhorn LH et al: Immediate adjuvant chemotherapy versus observation with treatment at relapse in pathological stage II testicular cancer. *N Engl J Med* 1987; **317**: 1433.
44. Motzer RJ, Sheinfeld J, Mazumdar M et al: Etoposide and cisplatin adjuvant therapy for patients with pathologic stage II germ cell tumors. *J Clin Oncol* 1995; **13**: 2700.
45. Fraley EE, Narayan P, Vogelzang NJ et al: Surgical treatment of patients with stages I and II nonseminomatous testicular cancer. *J Urol* 1985; **134**: 70.
46. Weissbach L, Bussar-Maatz R, Flechtner H et al: Rplnd or primary chemotherapy in clinical stage iia/b nonseminomatous germ cell tumors? Results of a prospective multicenter trial including quality of life assessment. *Eur Urol* 2000; **37**: 582.
47. Kollmannsberger C, Tandstad T, Bedard PL et al: Patterns of relapse in patients with clinical stage i testicular cancer managed with active surveillance. *J Clin Oncol* 2015; **33**: 51.
48. Chovanec M, Abu Zaid M, Hanna N et al: Long-term toxicity of cisplatin in germ-cell tumor survivors. *Ann Oncol* 2017; **28**: 2670.
49. Fung C, Fossa SD, Williams A et al: Long-term morbidity of testicular cancer treatment. *Urol Clin North Am* 2015; **42**: 393.
50. Travis LB, Fosså SD, Schonfeld SJ et al: Second cancers among 40,576 testicular cancer patients: focus on long-term survivors. *J Natl Cancer Inst* 2005; **97**: 1354.